

July-September 2016

ISSN 2222-5188

Volume 13 Issue 3

# Info **MEDICUS**

The essence of medical practice

## Contents

Review Article	3
Clinical Method	8
Case Review	10
Health News	11
Clinical Image	12
View Point	13
Info Quiz	15

### Editorial Board

M Mohibuz Zaman  
Dr. Rumana Dowla  
Dr. S. M. Saidur Rahman  
Dr. Tarek Mohammad Nurul Islam  
Dr. Tareq-Al-Hossain  
Dr. Adnan Rahman  
Dr. Fazle Rabbi Chowdhury  
Dr. Md. Islamul Hoque

### Published by

Medical Services Department  
ACI Limited  
Novo Tower, 9<sup>th</sup> Floor  
270 Tejgaon Industrial Area  
Dhaka-1208

### Designed by

Creative Communication Ltd.  
Road # 123, House # 18A  
Gulshan 1, Dhaka 1212

## Editorial

Dear Doctor,

We are very happy to present you the third issue of "Info Medicus" of 2016!

We convey our heartiest thanks for your important feedback about the second issue of this year and also delighted to have many of you participated in our Info Quiz competition.

Meningitis can be very serious if not treated quickly. It can cause life threatening blood poisoning and result in permanent damage to the brain or nerves. And acute bacterial meningitis is one of the top 10 causes of infection related death worldwide and many survivors suffer permanent neurologic sequelae. Although the annual incidence of bacterial meningitis is declining, it remains a medical emergency with a potential for high morbidity and mortality. In this view we have selected "Management of bacterial meningitis" in review article session.

The nose is the most frequently injured facial structure. In the setting of trauma to the anterior nasal septum, hematoma formation may occur. Although septal hematomas are rare, early diagnosis and treatment is important to prevent abscess formation, septal perforation, saddle nose deformity and potentially permanent complications. For this "Drainage of nasal septal hematoma" is portrayed in Clinical Method section.

Gonorrhoea is a common sexually transmitted infection (STI) caused by a type of bacteria *Neisseria gonorrhoeae*. Infection usually occurs in the genitals, but can affect the throat, eyes and rectum. It can even spread through the blood stream causing more widespread infection in some cases. If gonorrhoea remains untreated, there is a risk of passing the infection on to others. That's why in the View Point section, we have discussed "Gonorrhoea".

We have placed two clinical pictures with their explanation in Clinical Image section, which will be helpful for you to diagnosis such type of diseases in your daily practice.

Finally our best wishes are with you for your healthy life.

Thanks and best regards,



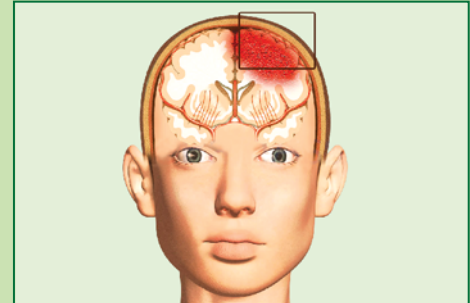
**(Dr. S. M. Saidur Rahman)**  
Medical Services Manager



**(Dr. Rumana Dowla)**  
Manager, Medical Information & Research

## Management of bacterial meningitis

Bacterial meningitis is a life threatening neurological and infectious disease. Acute bacterial meningitis (ABM) is one of the top 10 causes of infection related death worldwide and many survivors suffer permanent neurologic sequelae. The outcome of bacterial meningitis critically depends on the rapid initiation of bactericidal antibiotic therapy and adequate management of septic shock. Physicians must therefore have a considered approach to the patient with possible ABM in order to make the diagnosis and initiate appropriate therapies efficiently and effectively. Although the annual incidence of bacterial meningitis is declining, it remains a medical emergency with a potential for high morbidity and mortality. Clinical signs and symptoms are unreliable in distinguishing bacterial meningitis from the more common forms of aseptic meningitis, therefore a lumbar puncture with cerebrospinal fluid analysis is recommended. Empiric antimicrobial therapy based on age and risk factors must be started promptly in patients with bacterial meningitis. Concomitant therapy with dexamethasone initiated before or at the time of antimicrobial therapy has been demonstrated to improve morbidity and mortality in adults with *Streptococcus pneumoniae* infection. Almost 30 percent of strains of pneumococci, the most common etiologic agent of bacterial meningitis, are not susceptible to penicillin. However, bacterial meningitis with their pathophysiology, cause, diagnosis and management are described in this review.



### Pathophysiology

Pathogens enter the central nervous compartments either through the blood brain barrier or blood cerebrospinal fluid (CSF) barrier. Injury and mortality of bacterial meningitis is caused by the joint action of multiplying bacteria in the CSF and the released bacterial products, the local immune response of the brain and by granulocytes and monocytes invading the subarachnoid space and nervous tissue from the blood. The inflammatory cascade comprises pattern recognition receptors including toll like receptors (TLRs). The activation of myeloid differentiation factor 88 which interacts with various protein kinases, including IL-1 receptor associated pro-inflammatory molecules and the release of oxygen radicals.

The pathophysiology of bacterial meningitis involves a complex interplay between virulence factors of the pathogens and the host immune response. Much of the damage from this infection is believed to result from cytokines released within the CSF as the host mounts an inflammatory response. By production and release of virulence factors into and stimulation of formation of inflammatory cytokines within the central nervous system, meningeal pathogens increase permeability of the blood brain barrier, thus allowing protein and neutrophils to move into the subarachnoid space. There is then an intense subarachnoid space inflammatory response, which leads to many of the pathophysiologic consequences of bacterial meningitis, including cerebral edema and increased

intracranial pressure. An elevated intracranial pressure is very frequent in bacterial meningitis, most probably caused by the obstruction of the arachnoid granulations by leukocytes.

Most cases of bacterial meningitis begin with host acquisition of a new organism by nasopharyngeal colonization followed by systemic invasion and development of a high grade bacteremia. Bacterial encapsulation contributes to this bacteremia by inhibiting neutrophil phagocytosis and resisting classic complement mediated bactericidal activity. Central nervous system invasion then occurs, although the exact site of bacterial traversal into the central nervous system is unknown.

### Etiology

There are currently a number of bacteria that can lead to meningitis. Some of these include:

- *Neisseria meningitidis*
- *Streptococcus pneumoniae*
- Those who have a CSF shunt or have dural defects are likely to get meningitis caused by *Staphylococcus*
- Patients having spinal procedures (e.g., spinal anaesthesia) are at a risk of meningitis caused by *Pseudomonas* spp.

- Syphilis and tuberculosis leading to meningitis as well as fungal meningitis are rare causes but are seen in HIV positive individuals and those with a suppressed immunity

According to age group of the patient the most likely bacterial causes of meningitis include:

- In new borns: Pneumococcal bacteria or group B *streptococci*, *Listeria monocytogenes*, *Escherichia coli*
- Infants and young children: *H. influenzae* type b, in children less than 4 years and being unvaccinated raises risk of meningitis due to *Neisseria meningitidis*, *Streptococcus pneumonia*
- Older children and adults: *S. pneumoniae*, *H. influenzae* type b, *N. meningitidis*, Gram-negative bacilli, *Staphylococci*, *Streptococci* and *L. monocytogenes*
- Elderly and those with a suppressed immunity: *S. pneumoniae*, *L. monocytogenes*, tuberculosis (TB)

## Predisposing factors

Predisposing factors for meningitis include head trauma, immunosuppression, central nervous shunts, cerebrospinal fluid leak, neurological patients, alcoholism, sinusitis, otitis media, pharyngitis, bacterial pneumonia, sickle cell disease and congenital defects. Risk factors for meningitis can be summarized as follows:

- Age: Extremes of age specially elderly (age > 60 years), young children (age < 5 years) and infants (age < 2 years)
- Contiguous infection: Sinusitis, mastoiditis, otitis media or bacterial endocarditis
- Immuno compromising factors: Post splenectomy, hematologic disorder such as sickle cell disease or thalassemia major, malignancy, diabetes, cirrhosis or HIV
- Drugs: Non steroidal anti inflammatory drugs (NSAIDs), trimethoprim, sulfamethoxazole or immunosuppressive drugs
- Disease: Systemic lupus erythematosus

## Clinical presentation

The classical syndrome is characterized by fever, neck stiffness and altered mental status is present in 99 to 100 percent of patients with meningitis, when headache is

included, two of the four features are observed in 95 percent of patients with meningitis. The Kernig and Brudzinski signs are poorly sensitive but highly specific for bacterial meningitis. 63 percent of patients with meningococcal meningitis present with a rash that is usually petechial. Petechial rash may also be caused by *Haemophilus influenzae* or *Streptococcus pneumoniae* infection. Pneumococcal meningitis is more likely than meningococcal meningitis to be associated with seizures, focal neurologic findings, and altered consciousness. Compared with younger adults, persons 65 years and older with bacterial meningitis are less likely to have headache, nausea, vomiting, and nuchal rigidity, and are more likely to have seizures and hemiparesis. Similarly, the classical features of bacterial meningitis are not observed as often in younger children, who may present with subtle findings, such as lethargy and irritability. A recent history of upper respiratory tract infection is common in children with bacterial meningitis; children are also more likely than adults to experience a seizure. The illness course varies, with progression over hours to several days. The clinical features are nonspecific.

## Diagnosis

Bacterial meningitis is a significant cause of mortality and morbidity worldwide. If meningitis is suspected, samples of blood or cerebrospinal fluid are collected and sent to the laboratory for testing. It is important to know the specific cause of meningitis because that helps to understand how to treat the disease and possibly how bad it will get. Neurological outcome and survival depend largely on damage to CNS prior to effective antibacterial treatment.

### a. Cerebrospinal fluid (CSF)

Collection of cerebrospinal fluid (CSF) is an invasive technique and should be performed by experienced personnel under aseptic conditions. If meningitis is suspected, CSF is the best clinical specimen to use for isolating and identifying the etiological agents. The collection of CSF should be performed for diagnosis only. Despite typical CSF findings, the spectrum of CSF values in bacterial meningitis is so wide that the absence of one of more of the typical findings may not affect the diagnosis.

**Macroscopic examination:** By appearance, the CSF is normally clear like water. Cloudy, purulent, bloody or pigmented CSF as per the disease states.

- Hazy, cloudy, turbid CSF indicates either metastatic spread of tumors into the CNS or pleocytosis or severe meningeal infection

- Opalescent CSF may be suggestive of cryptococcal meningitis
- The turbid nature of the CSF is attributable to both the bacteria and leukocytes present
- Hemorrhagic CSF may be indicative of Anthrax meningitis with supportive clinical findings
- Frank clots or pellicles in CSF occur only if protein concentration exceeds 15g/l
- Xanthochromia of CSF is seen within 4 weeks of a cerebral hemorrhage
- In evaluating patients with suspected meningitis or encephalitis, a careful history along with biochemical and cellular analysis of CSF is required

**CSF glucose:** CSF glucose concentrations <45 mg/dl are indicative of bacterial meningitis. CSF glucose concentrations depend on serum concentrations and should always be tested on paired samples. The individual predictors of bacterial meningitis consists of a glucose concentration is <40 mg/dl and a ratio of CSF to blood glucose of <23 mg/dl. A CSF/serum ratio cut off of <0.4 is helpful in distinguishing between bacterial and aseptic meningitis.

**CSF protein:** CSF protein measurements of > 55 mg/dl are diagnostic of bacterial, fungal and tubercular meningitis.

**Cytological examination:** In untreated bacterial meningitis, the WBC count is elevated, usually in the range of 1000-5000 cells/mm<sup>3</sup>, although this range can be quite broad (<100 to >10,000 cells/mm<sup>3</sup>). Bacterial meningitis usually leads to a neutrophil predominance in CSF, typically between 80% and 95%; 10% of patients with acute bacterial meningitis present with a lymphocyte predominance (defined as >50% lymphocytes or monocytes) in CSF. Preponderance of CSF polymorphonuclear cells may be used to distinguish bacterial meningitis from other causes. It is important to note that a false positive elevation of the WBC which can be found in CSF after traumatic lumbar puncture, or in patients with intra cerebral or subarachnoid hemorrhage in which both red blood cells and white blood cells are introduced into the subarachnoid space.

**Culture:** In a world of increasing resistance to antibiotics and emerging pathogens, culture combined with susceptibility testing remains the gold standard for diagnosis to determine the causative organism in meningitis. Culture may be important for post neurosurgical or posttraumatic meningitis or for the investigation of CSF shunt meningitis.

**Latex Agglutination Test (LAT):** Tests are available to detect antigen in the CSF which are feasible at peripheral as well as intermediate laboratories where fundamental, preliminary facilities are not available. Of all these tests latex agglutination is a tool for screening and is rapid, sensitive, and specific less labour intensive, are highly sensitive and specific much more expensive than routine culture and are not available for routine use in developing countries.

## b. Other laboratory tests

**Blood cultures:** Blood cultures can be useful in a situation where CSF cannot be obtained before the administration of antimicrobials. Blood cultures can enhance the identification of the causative organism which follow haematogenous route to reach the meninges. Blood cultures are often positive and valuable to detect the causative organism and establish susceptibility patterns if CSF cultures are negative. Majority of the patients with bacterial meningitis have positive blood cultures.

Blood culture positivity differs for each causative organism:

- 50 to 90% of *H. influenzae* meningitis
- 75% of pneumococcal meningitis and
- 40% of children and 60% of adult patients with meningococcal meningitis

**Polymerase chain reaction (PCR):** Diagnosis of bacterial meningitis has long been based on classical methods of Gram stain, culture of CSF, and serological tests. The performance of these methods, especially culture and direct smear, is thwarted by failure to detect bacteria in pretreated cases and reluctance to perform lumbar punctures at admission. Indeed, patients with meningitis frequently receive antibiotics orally or by injection before the diagnosis is suspected or established. Thus an alternative method has become necessary to help clinicians and epidemiologists for the management and control of bacterial meningitis. Nucleic acid amplification tests such as PCR assays are highly sensitive and specific and have been evaluated for their effectiveness in detecting the presence of bacterial DNA in CSF from patients with suspected and proven bacterial meningitis.

**Flow cytometry:** Recently, flow cytometry with a dedicated bacterial channel has possible application in automated cell counting and this novel approach in the differential diagnosis of meningitis has been explored.

## Management

The initial treatment approach to the patient with suspected acute bacterial meningitis depends on early recognition of the meningitis syndrome, rapid diagnostic evaluation, and emergent antimicrobial and adjunctive therapy. Once there is suspicion of acute bacterial meningitis, blood samples must be obtained for culture and a lumbar puncture performed immediately to determine whether the CSF formula is consistent with the clinical diagnosis. In some patients, the clinician may not emergently perform the diagnostic lumbar puncture (e.g., secondary to the inability to obtain CSF), even when the diagnosis of bacterial meningitis is considered to be likely, or the clinician may be concerned that the clinical presentation is consistent with a CNS mass lesion or another cause of increased intracranial pressure and will thus order a CT scan of the head prior to lumbar puncture. In those patients in whom lumbar puncture is delayed or a CT scan is performed, however, there may be a significant interval between establishing the diagnosis of bacterial meningitis and initiating appropriate therapy. In these patients, blood samples must be obtained for culture and appropriate antimicrobial and adjunctive therapy given prior to lumbar puncture or before the patient is sent for CT. Delay in the initiation of therapy introduces the potential for increased morbidity and mortality, if the

### a. Recommended criteria for CT scan

Patients with suspected bacterial meningitis should undergo CT prior to lumbar puncture. After lumbar puncture, there is normally a mild, transient lowering of lumbar CSF pressure as a result of removal of CSF and continued leakage of CSF from the opening made in the arachnoid membrane that is rapidly communicated throughout the subarachnoid space. In patients with intracranial, space occupying lesions, there is a relative pressure gradient with downward displacement of the cerebrum and brainstem that can be increased by lumbar puncture, thereby precipitating brain herniation (Table 1).

### b. Use of antimicrobial agents in meningitis

Once the diagnosis of bacterial meningitis is established by CSF analysis, antimicrobial therapy should be initiated. Targeted antimicrobial therapy is based on presumptive pathogen identification by CSF Gram stain (Table 2), although the combination of vancomycin plus either ceftriaxone or cefotaxime is used for infants and children and recommended by some experts for adults with suspected bacterial meningitis. Empirical antimicrobial therapy is initiated either when the lumbar puncture is delayed (e.g., in those patients sent for CT of the head) or for patients with purulent meningitis and a negative CSF gram stain result (Table 3).

**Table 1: Recommended criteria for adult patients with suspected bacterial meningitis who should undergo CT prior to lumbar puncture**

Criteria	Comment
History of CNS disease	Mass lesion, stroke, or focal infection
New onset seizure	Within 1 week of presentation; some authorities would not perform a lumbar puncture on patients with prolonged seizures or would delay lumbar puncture for 30 min in patients with short, convulsive seizures
Papilledema	Presence of venous pulsations suggests absence of increased intracranial pressure
Focal neurologic deficit	Including dilated nonreactive pupil, abnormalities of ocular motility, abnormal visual fields, gaze palsy, arm or leg drift
Immunocompromised state	HIV infection or AIDS, receiving immunosuppressive therapy, or after transplantation

patient does indeed have acute bacterial meningitis. The choice of empirical antimicrobial therapy in this situation should be governed by the patient's age and by various conditions that may have predisposed the patient to meningitis.

The choice of specific antimicrobial agents for targeted or empirical therapy is based on the current knowledge of antimicrobial susceptibility patterns of these pathogens. For initial therapy, the assumption should be that antimicrobial resistance is likely.



**Table 2: Recommendations for antimicrobial therapy in adult patients with presumptive pathogen identification by positive gram stain**

Microorganism	Recommended therapy	Alternative therapies
<i>Streptococcus pneumoniae</i>	Vancomycin plus a third generation cephalosporin <sup>ab</sup>	Meropenem, fluoroquinolone
<i>Neisseria meningitidis</i>	Third generation cephalosporin <sup>a</sup>	Penicillin G, ampicillin, chloramphenicol, fluoroquinolone, aztreonam
<i>Listeria monocytogenes</i>	Ampicillin or penicillin G <sup>d</sup>	Trimethoprim plus sulfamethoxazole, meropenem
<i>Streptococcus agalactiae</i>	Ampicillin or penicillin G <sup>d</sup>	Third generation cephalosporin <sup>a</sup>
<i>Haemophilus influenzae</i>	Third generation cephalosporin <sup>a</sup>	Chloramphenicol, cefepime, meropenem, fluoroquinolone
<i>Escherichia coli</i>	Third generation cephalosporin <sup>a</sup>	Cefepime, meropenem, aztreonam, fluoroquinolone, trimethoprim plus sulfamethoxazole

Note: In children, ampicillin is added to the standard therapeutic regimen of cefotaxime or ceftriaxone plus vancomycin when *L. monocytogenes* is considered and to an aminoglycoside if a gram negative enteric pathogen is of concern.

a - Ceftriaxone or cefotaxime

b - Some experts would add rifampin if dexamethasone is also given

c - Gatifloxacin or moxifloxacin

d - Addition of an aminoglycoside should be considered

**Table 3: Recommendations for empirical antimicrobial therapy for purulent meningitis based on patient age**

Age	Common bacterial pathogens	Antimicrobial therapy
<1 month	<i>Streptococcus agalactiae</i> , <i>Escherichia coli</i> , <i>Listeria monocytogenes</i> , <i>Klebsiella</i> species	Ampicillin plus cefotaxime or ampicillin plus an aminoglycoside
1-23 months	<i>Streptococcus pneumoniae</i> , <i>Neisseria meningitidis</i> , <i>S. agalactiae</i> , <i>Haemophilus influenzae</i> , <i>E. coli</i>	Vancomycin plus a third generation cephalosporin <sup>ab</sup>
2-50 years	<i>N. meningitidis</i> , <i>S. pneumoniae</i>	Vancomycin plus a third generation cephalosporin <sup>ab</sup>
>50 years	<i>S. pneumoniae</i> , <i>N. meningitidis</i> , <i>L. monocytogenes</i> , aerobic gram negative bacilli	Vancomycin plus ampicillin plus a third generation cephalosporin <sup>ab</sup>

a - Ceftriaxone or cefotaxime.

b - Some experts would add rifampin if dexamethasone is also given.

## Conclusion

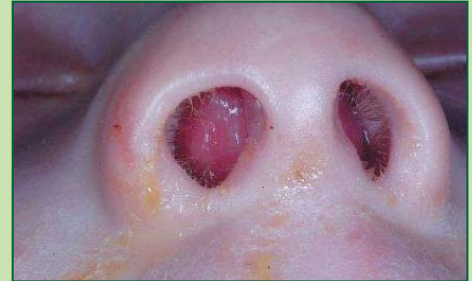The mortality rate in adults with bacterial meningitis in developed countries is high and it is higher in patients with pneumococcal disease than in those with meningococcal disease. Risk factors for adverse outcomes include advanced age, alteration of mental status, bacteremia and a CSF white blood cell count of less than 1,000 per  $\mu\text{L}$ . The mortality rate in children with bacterial meningitis is also high. Awareness of appropriate empiric and directed

antimicrobial therapy regimens may help to lower the morbidity and mortality rates.

- References:**
1. Empractic, Improving care through evidence, February 2011, Vol. 3, No. 2
  2. Am. Fam. Physician, December 15, 2010; Vol. 82, No. 12:1491-98
  3. Afr. J. Pharm. Pharmacol., May 15, 2014; Vol. 8, No. 18:469-478
  4. Clinical infectious diseases, November 1, 2004; Vol. 39:1267-84
  5. Clin. Microbiol. Rev., April 1, 1993; Vol. 6, No. 2:118-136
  6. Expert review of anti infective therapy, 2015
  7. WHO/CDS/CSR/EDC/99.7
  8. www.intechopen.com
  9. www.uptodate.com

## Drainage of nasal septal hematoma

Nasal injury is the most common type of facial trauma. It often occurs as a result of motor vehicle accidents, assaults, falls, sports injuries, and occupational injuries. Most nasal injuries do not require immediate intervention, but trauma that results in a septal hematoma is an exception. A septal hematoma is blood that collects in the space between the septal cartilage and the overlying perichondrium. A hematoma may deprive the septal cartilage of its blood supply from the overlying mucosa and thus may lead to permanent sequelae. Consequently, all patients with nasal trauma should be promptly evaluated for septal swelling. If a septal hematoma is present, the hematoma should be incised, drained, and packed to prevent recurrence. Prompt treatment of septal hematomas should prevent complications such as ischemia of the septal cartilage, which can lead to permanent necrosis and a saddle nose deformity. Such complications can occur rapidly. So, urgent hematoma drainage is indicated for all nasal septal hematomas.



### Anatomy

The nasal septum is composed of cartilaginous, membranous, and bony components overlaid by mucoperichondrium and mucoperiosteum. Bleeding within the confines of the mucoperichondrium leads to a septal hematoma, whereas external bleeding from Kiesselbach's plexus results in epistaxis.

### Anterior rhinoscopy

Examination of the nose can be accomplished with either an otoscope or a nasal speculum and headlight or an overhead light source. In case of using an otoscope, use an operating head attachment in case incision and drainage of the hematoma are required. Use of a nasal speculum is preferable, because it provides much wider exposure.

To avoid touching the sensitive nasal septum, insert the nasal speculum with the tips positioned superiorly and inferiorly. With proper exposure, it will be able to visualize the nasal septum, the inferior turbinate, and a portion of the middle turbinate (Figure 1)

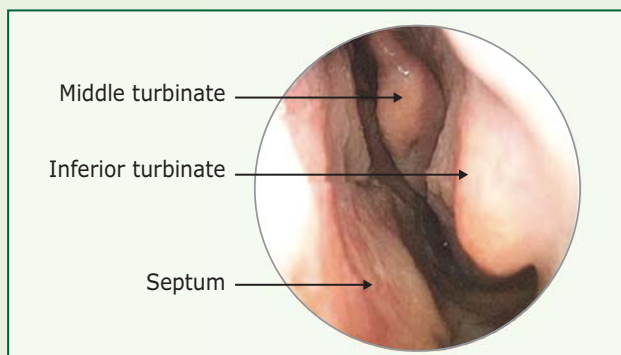


Figure 1: The nasal septum, inferior turbinate and middle turbinate

### Identification of nasal septal hematoma

Lateral bulging of the septum and fluctuance that persist after the nasal administration of a vasoconstrictive agent, such as oxymetazoline, are strongly suggestive of a nasal septal hematoma. An external nasal deformity may not be evident. A septal hematoma is highly likely in patients who had trauma or a sudden onset of nasal blockage that does not resolve with the removal of blood clots and the administration of a vasoconstrictive agent.

### Equipment

- A local anesthetic, such as 4% lidocaine mixed with a vasoconstrictor such as 0.05% oxymetazoline
- Cotton balls
- Thin pledgets and soaked in the topical anesthetic mixture; 1% or 2% lidocaine with epinephrine, at a dilution of 1:100,000
- A 1 cc syringe with a small needle for the injection of the lidocaine; a 5 to 10 cc syringe with an 18 or 20 gauge needle for aspiration of the hematoma
- A scalpel with a number 15 blade
- A headlight, bayonet forceps
- A nasal speculum
- A suction tipped catheter and
- Strip gauze or a nasal tampon

### Patient preparation

Anesthetize the nose with the cotton pledgets soaked in the mixture of lidocaine and oxymetazoline. Place the pledgets along the septum



in both nasal cavities for maximal coverage of the surface area. Topical anesthesia is usually achieved within 10 minutes, at which time one can remove the pledgets and inject a small amount of lidocaine with epinephrine into the superficial area of the septal epithelium. The mucosa will blanch in response to the epinephrine.

## Management

- If a septal abscess is suspected, needle aspiration under topical anesthesia can be performed using an 18 to 20 gauge needle
- Except in patients who present immediately after hematoma formation, specimens should be sent for gram stain and aerobic and anaerobic cultures. Systemic antibiotics should then be administered
- To drain the hematoma, incise the mucosa (using a hemostat) over the area of greatest fluctuance without incising cartilage (Figure 2). Bilateral staggered incisions should be made for bilateral hematomas to avoid a through and through perforation
- Suction out the clot; then irrigate with sterile normal saline
- A small section of the mucoperichondrium should be excised to prevent premature closure of the incision
- Place a small penrose drain and suture it in place
- Insertion of sterile gauze to prevent the reaccumulation of blood

Finally, pack both nostrils, as in anterior epistaxis, to re-approximate the perichondrium to the cartilage. The drain and packing remain in place until the drainage stops for 24 hours; this usually takes 2-3 days.

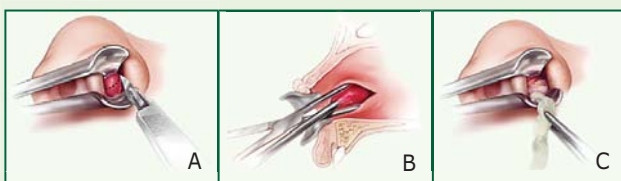

Figure 2: Management of septal hematoma. (A) incision using a hemostat (B) drainage of the hematoma (C) insertion of sterile gauze to prevent the reaccumulation of blood

## Nasal packing

Nasal packing is required to prevent the development of another hematoma or a seroma. The two main types of nasal packing are sterile gauze impregnated with petroleum jelly and the nasal tampon.

**Sterile gauze:** Using a nasal speculum and headlight, grasp the bayonet forceps and layer ¼ inches gauze impregnated with petroleum jelly into each of the nasal cavities. Let the free end of the ribbon like gauze protrude slightly from the nose and then loop it backward along the floor of the nose. Continue to loop the gauze from the floor

of the nose upward. This sequence ensures an orderly placement that will allow for compression. Let the very end of the petroleum impregnated gauze protrude from the nares. Once the packing the gauze is completed, it will fill the nasal cavity and should prevent the reaccumulation of the hematoma. The use of one continuous strip prevents any packing material from being left in the nasal passage during removal. The application of gauze packing is time consuming and can be uncomfortable for the patient. Once in place, the packing material may adhere to the nasal mucosa, complicating removal.

**Nasal tampon:** Use a nasal speculum and forceps to insert the nasal tampon along the septum and in the same horizontal plane as the ear lobe. Continue to insert the pack until its end is at the nares. Once the pack is in place, use a syringe to impregnate it with sterile saline solution. The pack should expand to fill the anterior nasal cavity. This expansion of the pack will provide compression and will prevent the formation of another hematoma or a seroma. Insertion of the nasal tampon requires less time than the layering of the gauze and is more comfortable for the patient.

The packing material is left in place for 3 days. While the gauze or nasal tampon is in place, patients should take an antibiotic that will guard against staphylococcal infection.

## Resolution of hematoma

With the resolution of the hematoma, the septum will generally heal within 1 week, without any evidence of the incision. The mucosa should appear healthy and smooth.

## Complications

The most common early complication is the formation of a seroma that is the result of fluid reaccumulation that occurs after the nasal packing material has been removed. Aspirate the seroma and place new packing material as needed, as in the initial treatment of the hematoma. Hematomas are susceptible to secondary infection, which can usually be prevented by starting the patient on an antibiotic regimen immediately after the procedure and continuing the treatment while the nasal pack is in place. If an abscess is present, send a specimen for culture. Culture directed therapy will help avert dangerous late sequelae, including the intracranial extension of a septal abscess. If the hematoma is not promptly drained, the septal cartilage may be destroyed. In such cases, a saddle nose deformity may develop.

## Summary

The routine examination of the nasal septum after trauma will allow for early identification and treatment of a nasal septal hematoma. Prompt treatment will help prevent unnecessary complications and can be performed in a wide variety of clinical settings.

- References:**
1. *N. Engl. J. Med.* 28 May 2015; 372; 22: e28 (1-3)
  2. *Am. Fam. Phy.*, October 1, 2004. Vol. 70, No. 7:1315-20
  3. [www.emedicine.medscape.com](http://www.emedicine.medscape.com)

### Multiple chest wall swellings in adult Burkitt's lymphoma

A 64 year old male farmer presented with a 3 month history of painless, progressive swelling of his chest wall and lower jaw, and 10 kg unintentional weight loss. On examination he had multiple lumps about 3 × 1.5 cm around the angle of the mandible, and multiple 10 × 8 cm lumps at the mid sternal region and of the left lower anterior chest wall (Figure). These lumps were non tender to palpation, hard, and tethered, with irregular contours, no temperature changes or overlying skin changes.

Blood tests were normal and HIV serology was negative. CT Chest showed a soft tissue mass 8 × 10.6 × 8 cm encasing and eroding the body of sternum with presternal and retrosternal soft tissue components, and whole body PET CT fusion showed increased 18F-fluorodeoxyglucose (18F-FDG) uptake. Histological and immunohistochemical examination of a biopsy specimen from the chest wall swelling showed tightly packed small round cells with high mitotic activity infiltrating fat and starry sky appearance, positive for CD20, Bcl-2, Mum-1, and Bcl-6, and negative for CD10, CD3, Cyclin-D1, and TdT, with Ki-67 nearly 100%.

Conventional cytogenetics showed complex structural and numerical abnormalities. This case is diagnosed as high risk group adult Burkitt's lymphoma stage IV, and started treatment with modified Magrath regimen of four alternating cycles of R-CODOX-M and R-IMVAC chemotherapy. The patient achieved complete remission with disappearance of sterna swellings, normal peripheral blood counts, normal bone marrow aspirate, and no evidence of 18FDG uptake on repeat PET scan. He remained in remission at last 3 month follow up.

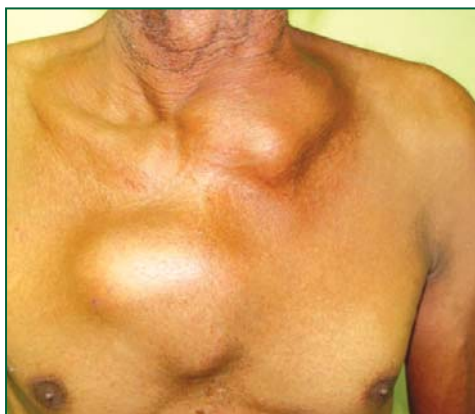

Figure: Adult Burkitt's lymphoma; multiple non tender chest wall swellings

Burkitt's lymphoma is a form of non Hodgkin's lymphoma in which cancer starts in immune cells called B cells. Recognized as the fastest growing human tumor, Burkitt lymphoma is associated with impaired immunity and is rapidly fatal if left untreated. However, intensive chemotherapy can achieve long term survival in more than half the people with Burkitt's lymphoma. Because Burkitt's lymphoma spreads so quickly, prompt diagnosis is essential. If Burkitt's lymphoma is suspected, all or part of an enlarged lymph node or other suspicious disease site will be biopsied. Burkitt's lymphoma can spread to the fluid surrounding the brain and spinal cord, chemotherapy drugs should be injected directly into the cerebrospinal fluid.

**References:** 1. The lancet, December 20/27, 2014; Vol. 384:2244  
2. www.webmd.com

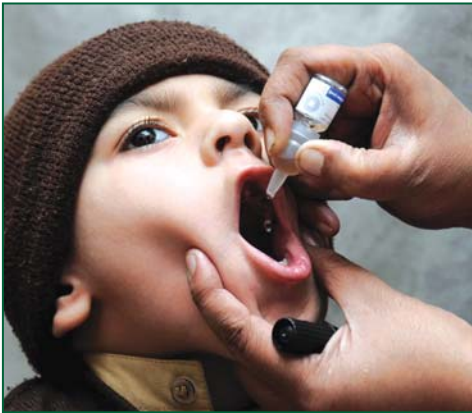#### Info Quiz Participants

- Have you selected the correct answer(s) you still have time to put your entry submission together for info Quiz Prize
- The closing date for entries is 25 July 2016
- We look forward to receive your winning entry

#### Info Quiz Answer

April-June 2016

- |            |            |
|------------|------------|
| 1. a, c, d | 6. a, c, e |
| 2. a, d, e | 7. b, c    |
| 3. a, c, e | 8. b, c, e |
| 4. b, c, d | 9. c, d, e |
| 5. a, c, d | 10. e      |



## Vaccine switched in 'milestone' towards ending polio

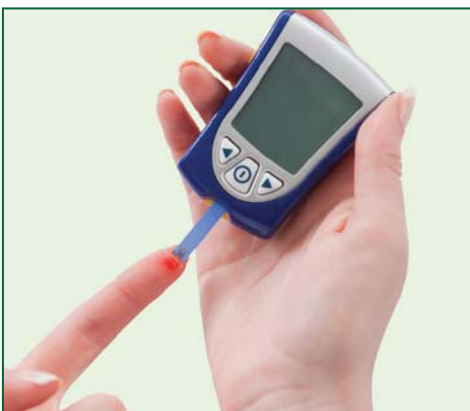
More than 150 countries have begun switching to a different polio vaccine - an important milestone towards polio eradication. The new vaccine will target the two remaining strains of the virus under a switchover 18 months in the planning. There is no longer including a weakened version of type 2 polio virus, which was eradicated in 1999. There were just 74 cases of the paralysing disease in 2015 and there have been 10 so far in year 2016. All of the cases were in Afghanistan and Pakistan. Africa has been free of polio for more than a year. Previous vaccine can mutate and lead to polio in very rare cases. So removing type 2 from the vaccine takes away that risk and ensures that new vaccine will work better dose by dose. The new vaccine will still be given as drops in the mouth, so healthcare workers will not need fresh training.

*Reference:* [www.bbc.com/health](http://www.bbc.com/health)

## E-skin can monitor body's oxygen level

Scientists said they have developed ultra thin electronic "skin" that can measure oxygen levels when stuck to the body. The goal is to develop such device to monitor oxygen levels in organs during surgery. Lead researcher Tomoyuki Yokota and colleagues said "The device unobtrusively measures the oxygen concentration of blood when laminated on a finger and flexible organic optical sensors may be directly laminated on organs to monitor the blood oxygen level during and after surgery". The device contains micro electronic components that light up in red, blue and green on the surface of the body. Scientists at the University of Tokyo are working on ways to display numbers and letters on the skin for health monitoring purposes. Wearable electronics are a future growth area in research, with interest in medical applications such as contact lenses that monitor glucose levels.

*Reference:* [www.bbc.com/health](http://www.bbc.com/health)



## Type 1 diabetes prevention trial starts in Scotland

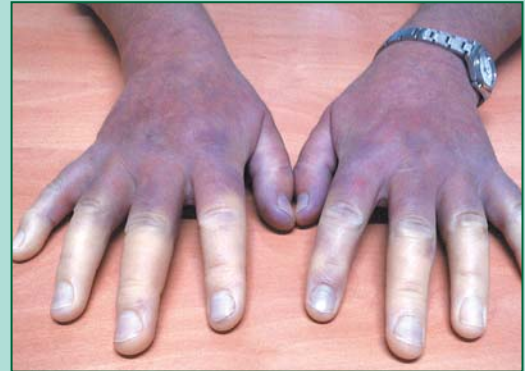A major trial is set to start in Scotland aimed at preventing Type 1 diabetes in children. Researchers are preparing to contact all 6,400 families in the country affected by the condition. Children who have a parent or sibling with Type 1 diabetes will be invited for a blood test to see if they are at high risk of developing the disease. Those at risk will be offered a drug called Metformin to see if it can hold off diabetes. Metformin is already used to treat diabetes, but it is not clear if it might prevent it from developing. Type 1 diabetes develops when the body does not produce insulin. And it is happened when immune system mistakenly attack  $\beta$  cells of pancreas. The main cause of damage is stress on the  $\beta$  cells as they struggle to cope with demand for insulin. Rather than focusing on halting the immune system, Prof Wilkin says it could be better to work on protecting the  $\beta$  cells. He hopes Metformin will relieve the stress on the  $\beta$  cells, so they can continue to make insulin. If successful, the study could challenge long established thinking on what lies behind Type 1 diabetes.

*Reference:* [www.bbc.com/health](http://www.bbc.com/health)

## Image 1

### Cold hands associated with scleroderma

A 45 year old woman presented with cold hands. These symptoms had developed over a period of 6 years. Raynaud's phenomenon was seen after her hands were exposed to cold. The antinuclear antibody titer was greater than 1:1280, with an anticentromere antibody pattern. This pattern may be present in 40 to 80% of patients with limited scleroderma, and secondary Raynaud's phenomenon may be seen in 80 to 90% of such patients. In 30% of patients with secondary Raynaud's phenomenon, it may be an early presentation of scleroderma. The patient's blood pressure was 135/95 mm Hg at presentation and she had no other symptoms except skin thickening. Initial treatment was a calcium channel blocker. Laboratory testing during follow up showed mild lymphopenia (1540 lymphocytes



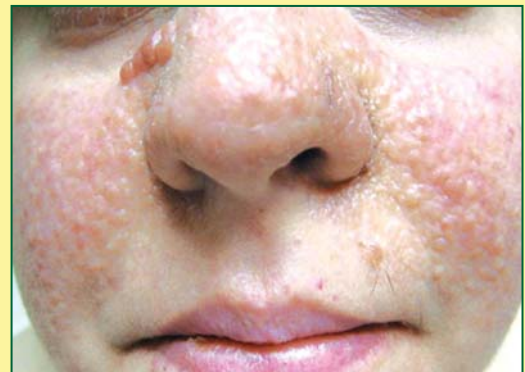per cubic millimeter) and a creatinine level of 0.70 mg per deciliter (60  $\mu$ mol per liter). The patient wears gloves to protect her hands in cold weather.

**Reference:** *N. Eng. J. Med.*, October 24, 2013; 369:17:1638

## Image 2

### Facial angiofibromas associated with tuberous sclerosis

A 29 year old woman presented with a long standing history of yellow orange papules on her nose and cheeks, skin colored papules at the proximal nail fold of several toes, and a skin colored plaque on her back. These findings were diagnosed as facial angiofibromas, periungual fibromas, and a shagreen patch, respectively. They are characteristic of tuberous sclerosis, an autosomal dominant disorder in which mutations in tumor suppressor gene TSC1 or TSC2 result in the formation of benign hamartomas throughout the body. Previous computed tomography of the brain had shown such hamartomas in the patient. Almost all patients with this condition have at least one characteristic dermatologic feature. Central nervous system manifestations are a common source of morbidity, including infantile spasms, seizures, intellectual disability,



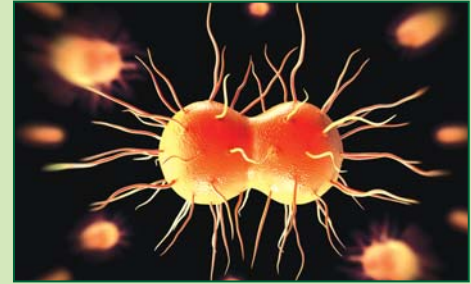
and giant cell astrocytomas. Many other organ systems may be involved. Proper identification of the dermatologic features of tuberous sclerosis may aid in the diagnosis of the condition and ultimately help to initiate appropriate screening examinations and genetic counseling.

**Reference:** *N. Eng. J. Med.*, March 17, 2011; 364:11:1061



## Gonorrhoea

Gonorrhoea remains a major bacterial sexually transmitted infection which is frequently asymptomatic at the endocervix and urethra in women, and usually asymptomatic in the rectum and oro-pharynx in both men and women. In men, uncomplicated urethritis is the most common manifestation, with dysuria and urethral discharge. Less typically, signs and symptoms are mild and indistinguishable from those of chlamydial urethritis. In women, the most common site of infection is the uterine cervix, where infection results in symptoms (such as vaginal discharge, lower abdominal discomfort, and dyspareunia) in less than one half of cases.



### Etiology

Gonorrhoea is the condition of being infected with the Gram negative diplococcus *Neisseria gonorrhoeae*. Primary sites of infection are the mucous membranes of the urethra, endocervix, rectum, pharynx and conjunctiva. Transmission is by direct inoculation of infected secretions from one mucous membrane to another. An important minority of infections are transmitted from mother to child during birth.

### Clinical features

#### a. Symptoms

##### Men

- Urethral infection commonly causes urethral discharge and dysuria, starting within 2 to 5 days of exposure
- Rectal infection is usually asymptomatic but may cause anal discharge, perianal pain or discomfort
- Urethral and pharyngeal infection is usually asymptomatic

##### Women

- Increased or altered vaginal discharge is the most common symptom
- Lower abdominal pain may be present
- Urethral infection may cause dysuria but not frequency
- Gonorrhoea is a rare cause of intermenstrual bleeding or menorrhagia
- Rectal and pharyngeal infection is usually asymptomatic

#### b. Signs

##### Men

- A mucopurulent or purulent urethral discharge is commonly evident

- Rarely, epididymal tenderness or swelling or balanitis may be present

##### Women

- Mucopurulent endocervical discharge and easily induced endocervical bleeding
- Pelvic or lower abdominal tenderness

### Diagnosis

- The diagnosis of uncomplicated gonorrhoea is established by identification of *N. gonorrhoeae* in genital, rectal, pharyngeal or ocular secretions
- *N. gonorrhoeae* can be detected by nucleic acid amplification tests (NAATs) or culture. The bacterium can also be visualized on microscopy of stained genital tract smear to facilitate rapid diagnosis in symptomatic patients. No test offers 100% sensitivity and specificity
- Microscopy (×1000) using Gram or methylene blue staining for identification of diplococci within polymorphonuclear leukocytes offers good sensitivity (>95%) and specificity as a rapid diagnostic test in symptomatic men with urethral discharge. Microscopy has poor sensitivity (<55%) in asymptomatic men and in identifying endocervical (<55%) or rectal infection (<40%) and cannot be recommended as a test of exclusion in these situations. Microscopy is not recommended for identification of pharyngeal infection due to poor specificity as well as low sensitivity
- Culture offers a specific and cheap diagnostic test that readily allows confirmatory identification. It is the only diagnostic test that enables antimicrobial susceptibility testing and capacity to perform culture remains essential to detect and monitor evolving antimicrobial resistance. Culture is appropriate for

endocervical, urethral, rectal, pharyngeal and conjunctival specimens but not for urine. Culture should be performed for antimicrobial sensitivity testing in patients with persisting infection or symptoms following treatment or if treatment failure is suspected

- Nucleic acid amplification tests (NAATs) are significantly more sensitive than culture for detecting pharyngeal and rectal infection and are the test of choice for screening for rectal and pharyngeal gonococcal infection. NAATs are generally more sensitive than culture and offer testing on a wider range of specimen types. NAATs show high sensitivity (>96%) in both symptomatic and asymptomatic infection

## Management

### a. Treatment of uncomplicated gonorrhoea

- Ceftriaxone 500 mg intramuscularly as a single dose with azithromycin 1 g oral as a single dose
- Azithromycin is recommended as co-treatment irrespective of the results of chlamydia testing, to delay the onset of widespread cephalosporin resistance

Alternative regimens: It is recommended to regularly review local and national trends in gonococcal antimicrobial resistance. All the agents below should be accompanied by azithromycin 1 g oral as a single dose.

- Cefixime 400 mg oral as a single dose. Only advisable if an intramuscular injection is contraindicated or refused by the patient
- Spectinomycin 2 g intramuscularly as a single dose

### b. Treatment of complicated gonorrhoea

Gonococcal PID: Ceftriaxone 500 mg intramuscularly immediately followed by oral doxycycline 100 mg twice daily plus metronidazole 400 mg twice daily for 14 days.

Gonococcal epididymo-orchitis: Ceftriaxone 500 mg intramuscularly plus doxycycline 100 mg twice daily for 10-14 days.

Gonococcal conjunctivitis: A three day systemic regimen is recommended as the cornea may be involved and is relatively avascular. The eye should be irrigated with saline or water.

- Ceftriaxone 500 mg intramuscularly daily for three days
- If history of penicillin anaphylaxis or established cephalosporin allergy: spectinomycin 2 g intramuscularly immediately daily for three days or azithromycin 2 g oral immediately plus doxycycline 100 mg twice daily for one week plus ciprofloxacin 250 mg daily for three days

### c. Treatment of disseminated gonococcal infection

- Ceftriaxone 1 g intramuscularly or intravenous every 24 hours or cefotaxime 1 g intravenous every eight hours

or ciprofloxacin 500 mg intravenous every 12 hours (if the infection is known to be sensitive) or spectinomycin 2 g intramuscularly every 12 hours

- Therapy should continue for seven days but may be switched 24-48 hours after symptoms improve to one of the following oral regimens: cefixime 400 mg twice daily, ciprofloxacin 500 mg twice daily or ofloxacin 400 mg twice daily

### d. Treatment during pregnancy and breastfeeding

Pregnant and breastfeeding women should not be treated with quinolone or tetracycline antimicrobials. Azithromycin should use only if adequate alternatives are not available. Pregnancy does not diminish treatment efficacy. Recommended regimens are ceftriaxone 500 mg intramuscularly as a single dose with azithromycin 1 g oral as a single dose or spectinomycin 2 g intramuscularly as a single dose with azithromycin 1 g oral as a single dose.

### e. Treatment in pharyngeal infection

Single dose antimicrobials treatments have in general demonstrated lower efficacy (<90%) in eradicating *N. gonorrhoeae* from the pharynx than in eradicating genital infection. Failure has even been reported with ceftriaxone. Recommended treatments are ceftriaxone 500 mg intramuscularly as a single dose with azithromycin 1 g as a single dose or ciprofloxacin 500 mg orally as a single dose if *N. gonorrhoeae* known to be quinolone sensitive or ofloxacin 400 mg orally as a single dose if *N. gonorrhoeae* known to be quinolone sensitive. Single dose treatment with spectinomycin has poor efficacy in eradicating gonococcal infection of the pharynx.

### f. Treatment for sexual partners

- Patients with infection at other sites or asymptomatic infection should notify all partners within the preceding three months. Sexual partners should be offered testing and treated for gonorrhoea
- Patients should be advised to abstain from sexual intercourse until they and their partner(s) have completed treatment. If azithromycin is used, this will be 7 days after treatment was given

## Complications

Translational spread of *N. gonorrhoeae* from the urethra or endocervix may occur to cause epididymo-orchitis or prostatitis in men and pelvic inflammatory disease (PID) in women. Haematogenous dissemination may also occur from infected mucous membranes to cause skin lesions, arthralgia, arthritis and tenosynovitis. Gonococcal bacteraemia rarely occurs (less than 1% of infections) and is usually manifested by skin lesions, fever, arthralgia, acute arthritis and tenosynovitis.

#### References:

1. National Guideline on the Diagnosis and Treatment of Gonorrhoea in Adults, 2005
2. European Guideline on the Diagnosis and Treatment of Gonorrhoea in Adults, 2012



## Refresh your memory

Please select the correct answer by (✓) against a, b, c, d, e of each question in the Business Reply Post Card and sent it through our colleagues or mail within 25 July 2016; this will ensure eligibility for the Raffle Draw and the lucky winners will get attractive prizes!

**1. Herpes simplex infection -**

- a) is commonly associated with carcinoma of the uterus
- b) may cause Kaposi's varicelliform eruptions
- c) may cause keratoconjunctivitis
- d) may cause subacute sclerosing panencephalitis
- e) may cause acute gingivostomatitis

**2. In measles -**

- a) a morbilliform erythema is observed
- b) a suboccipital lymphadenopathy is continuously present
- c) lymphopenia is a common complication
- d) arthritis is a possible complication
- e) frequent relapses are observed

**3. In which following conditions inflammatory arteritis is typically seen?**

- a) Polyarteritis nodosa
- b) Aortic arch syndrome
- c) Rheumatic fever
- d) Henoch Schönlein purpura
- e) Endarteritis obliterans

**4. Recognized causes of a radiologically detected paraspinal calcification include -**

- a) Fluorosis
- b) Rickets
- c) Hypoparathyroidism
- d) Familial hypophosphatemia
- e) Thyrotoxicosis

**5. Which of the following conditions or drugs inhibit uric acid reabsorption?**

- a) Low dose salicylate
- b) Hyperlactacidemia
- c) Phenylbutazone
- d) Dicoumarol
- e) Probenecid

**6. What are the causes of the lack of antidiuretic hormone?**

- a) A suprasellar tumor
- b) Healed tuberculous meningitis
- c) Phenylbutazone therapy
- d) Dicoumarol
- e) Probenecid

**7. What are the indications for steroid therapy?**

- a) Atopic dermatitis
- b) Sarcoidosis
- c) Cushing's syndrome
- d) Pemphigoid
- e) Hereditary spherocytosis

**8. Skin lesions associated with syphilis are -**

- a) copper colored bullous lesions
- b) unilateral hyperkeratosis of the sole
- c) condyloma acuminatum
- d) mucocutaneous lesions
- e) moderately elevated circular ulcerations

**9. A 3 year old child loses his appetite and subsequently refuses food. What are the possible causes?**

- a) An early onset of schizophrenia
- b) Negative behavior
- c) Daydreaming
- d) Anorexia nervosa
- e) Parents have spoiled the child

**10. What are the characteristics of delirium tremens?**

- a) Marked drowsiness
- b) A gradual onset
- c) Visual hallucinations
- d) Bradycardia
- e) Illusions



**ADVANCING**  
**POSSIBILITIES**